

Effect of individualised Homoeopathy in the treatment of infertility

Suraia Parveen*, Himadri Bhaumik

Dr. Anjali Chatterjee Regional Research Institute for Homoeopathy, Kolkata, West Bengal, India

Abstract

A 37-year-old woman, being married for 6 years, presented to the homoeopathic outpatient department, after treatment of infertility by a gynaecologist for few years. She had a past history of emergency ovarian cystectomy for endometriosis 1 year after her marriage. Her subsequent infertility workup revealed hydrosalpinx with one-sided tubal block along with the evidence of poor ovarian reserve. Her husband's semen analysis was normal and was advised for donor-ovum *in vitro* fertilisation. At this point, she was treated with constitutional homoeopathic medicine following the miasmatic analysis with the holistic concept of Homoeopathy over 6 months. Treatment started with *Silicea* and later switched to *Syphilinum*. She conceived normally after that and subsequently delivered a healthy baby at full term. This case shows the positive role of classical homoeopathic treatment on subfertility.

Keywords: Endometriosis, Homoeopathy, Infertility, Poor ovarian reserve, *Silicea*, *Syphilinum*

INTRODUCTION

The World Health Organization has defined infertility as a disease of the reproductive system characterised by the failure to achieve pregnancy after 12 months or more of regular unprotected sexual intercourse. Infertility may be broadly subdivided into primary and secondary infertility. Primary infertility is infertility in a couple who never had a child, whereas secondary infertility is failure to conceive following previous live birth of a child.^[1,2]

Data from population-based studies suggest that 10%–15% of couples in the world experience infertility. Infertility may be due to specific pathology in male (20%–30%) and/or female reproductive system (20%–35%); however, often, the cause is multifactorial (25%–40%) or remains unexplained (10%–20%).^[3] However, literature reviews failed to reveal any Indian demographic data. Among female pathology, there may be either ovulatory dysfunction or structural problems in fallopian tubes and other reproductive system or combined pathology in an almost equal proportion. Ovulatory dysfunctions may be caused by either problems in ovaries such as oophoritis, ovarian tumours, decreased/poor ovarian reserve (POR) and corpus luteum insufficiency or systemic metabolic/endocrine disorders such as polycystic

ovarian syndrome, hypothyroidism, hyperthyroidism and hyperprolactinaemia. Reproductive structural problems may be caused by pelvic inflammatory diseases, endometriosis, fibroids or congenital problems.^[4]

Endometriosis is an enigmatic gynaecological pathology defined by the presence of tissue similar to uterine endometrium at places other than physiologically appropriate area, i.e., uterine endometrial cavity. There are two classical, well-differentiated types of endometriosis in both clinical manifestations and aetiopathogenesis, namely (1) adenomyosis or internal endometriosis where ectopic endometrial foci infiltrate the outer muscular walls of the uterus and (2) external endometriosis or simply endometriosis where ectopic endometrial foci infiltrate in the pelvic cavity commonly, or distantly at abdominal cavity or even outside. Usually, the common symptoms of endometriosis are dysmenorrhoea, deep

***Address for correspondence:** Dr. Suraia Parveen,
Dr. Anjali Chatterjee Regional Research Institute for Homoeopathy,
50, Rajendra Chatterjee Road, Kolkata - 700 035, West Bengal, India.
E-mail: drsuraia@gmail.com

Received: 25.05.2018; **Accepted:** 26.12.2018

Access this article online

Quick Response Code:



Website:
www.ijrh.org

DOI:
10.4103/ijrh.ijrh_33_18

This is an open access journal, and articles are distributed under the terms of the Creative Commons Attribution-NonCommercial-ShareAlike 4.0 License, which allows others to remix, tweak, and build upon the work non-commercially, as long as appropriate credit is given and the new creations are licensed under the identical terms.

For reprints contact: reprints@medknow.com

How to cite this article: Parveen S, Bhaumik H. Effect of individualised Homoeopathy in the treatment of infertility. Indian J Res Homoeopathy 2018;12:231-9.

dyspareunia and chronic pelvic pain.^[5,6] There may be infertility in 30% of cases of endometriosis. Infertility in endometriosis is usually caused by tubal blockage or interference with implantation.^[7] Severe endometriosis in the ovary may lead to chocolate cyst, tubo-ovarian mass with adhesion of the fallopian tubes or acute ovarian-torsion requiring surgery.^[8] Ovarian reserve (OR) determines the capacity of the ovary to provide oocytes that are capable of fertilisation resulting in a healthy and successful pregnancy. During menstrual cycle, certain hormones such as follicle-stimulating hormone (FSH), anti-Mullerian hormone (AMH) and estradiol (E2) are used to assess the reproductive quality of the oocytes parallel to the antral follicle count (AFC). Increasing maternal age affects ovarian function both in quality and quantity of oocytes by which, with increasing age, a woman gradually progresses from infertility to menopause. While menopause occurring before the age of 40 years is called premature ovarian failure (POF), subfertility with preserved menstruation in younger women is considered as POR or early ovarian ageing.^[9] Since AMH is solely produced in the growing ovarian follicles, its serum level is used as a marker for OR or the quality of the ovarian follicle pool.^[10] FSH helps in the maturation of ovarian follicles and in decreased growing follicle in the ovary; the serum FSH level goes higher indirectly as a compensatory mechanism of the brain and the women who ovulate early may have elevated.^[11] E2 levels above 80 pg/mL will mask an elevated FSH level.^[12] Thus, decreased AMH, decreased E2 and raised FSH on days 2–4 of menstrual cycle indicate POR in a female. The primary and prominent indication for egg donation was originally for women with POF, but, in recent years, for women with POR. Females with decreased AMH and raised FSH on days 2–4 of menstrual cycle when fail to show progress in growing AFC on optimum hormonal ovarian stimulation are finally the candidates for *in vitro* fertilisation (IVF) with egg donation.^[13]

Here, we presented a case of successful homoeopathic treatment of primary infertility in a female who was long been treated for endometriosis, undergone emergency laparotomy with removal of tubo-ovarian mass, finally diagnosed as a case of decreased OR/POR and advised for IVF with donated egg.

CASE REPORT

A 37-year-old, Hindu, married woman from low-middle socioeconomic status family presented at Dr. Anjali Chatterjee Regional Research Institute for Homoeopathy (DACRRIH), Kolkata, in July 2015, with a complaint of having no child since 6 years of her marriage despite long-term treatment by gynaecologists and fertility specialists. Her husband's semen analysis report was normal. Her menstrual cycle was irregular, with moderate flow lasting for 2–3 days with associated dysmenorrhoea.

She got married in 2009 and used to suffer from dyspareunia and recurrent pain in the lower abdomen. In June 2010, she was admitted to a nursing home with acute pain abdomen and diagnosed with a large space-occupying lesion is modified to-a large cystic SOL (space-occupying

lesion) (4.3 cm × 4.0 cm × 4.1 cm) in the right ovary/adnexa. There was a history of recurrent appendicitis. On 14 June 2010, right ovarian cystectomy and appendicectomy were done. In 2011, she was worked up by a gynaecologist for the treatment of infertility. On 30 March 2011, hysteroscopy revealed a congested uterus, hyperplastic with both ostia seen. On laparoscopy, right ovary and right fallopian tube were not visualised but showed extensive endometriosis surrounding the left ovary and the left tube was looking healthy but with no spillage. After that, she continued her endeavour for natural conception along with on-off treatment by different gynaecologists over the next few years. Finally, being unsuccessful, she went to a fertility specialist in January 2015. She underwent thorough investigation such as hysterosalpingogram (HSG), transvaginal ultrasonography (TVS USG), serum for AMH, FSH and serial folliculometry with hormonal ovulation induction. After complete evaluation, the fertility specialist suggested her for IVF with donor ovum. The patient did not have financial ability for bearing the expenses of IVF, so she finally landed up at DACRRI for homoeopathic treatment for her infertility.

There was a history of typhoid at 7 years of age and tonsillectomy at the age of 12 years. Currently, she has an additional morbidity of small fibroadenoma in the left breast for 1 year.

As for her family, there was a history of chronic obstructive pulmonary disease in her father, osteoporosis and lumbar spondylosis in her mother, unspecified mental illness in her maternal uncle at old age and her maternal grandfather died from liver cancer.

Homoeopathic generalities

Mental expressions, physical makeup, physical generals, etc., were considered for totality of symptoms as follows:

Mental generals

She was extremely anxious for her issue. She was usually sad, depressed and frustrated in life because of ending of hope to conceive. She prefers being alone and a quiet environment. She is very much irritable and angered easily, and small things would affect her. She has also obsessive behaviour, i.e., washing habit and always busy to clean home. She is also forgetful, indecisive and hesitated to take decision with lack of self-confidence.

Physical generals

She was dark complexioned, emaciated with pointed forehead and looked older than age. Her menses were usually painful, irregular, late, scanty flow, dark and clotted, offensive and pain occurs before and during menses. She has leucorrhoea – thick, acrid mucus < after menses, with itching in vagina and vulva pudenda. She also had decreased appetite, moderate thirst with recurrent ulceration of mouth and tongue, caries teeth with decayed edges and disturbed sleep < first night. She has the tendency of constipation from childhood, with passing dry, hard, stool, at 2–3 days' interval. She was also thermally ambithermic, She craves spicy food⁺⁺⁺ and cold food⁺⁺⁺ and dislikes bread⁺. Moreover, she has profuse sweat in all over the body, offensive, more on the palm and sole.

As per the principles of Homoeopathy, to construct the totality, detailed case taking and evaluation of the characteristic symptoms were done. Using the RADAR 10 software (Synthesis, Repertorium Homeopathicum Syntheticum 9.1 version), Archibel Homoeopathic Software, Belgium, 2009,^[14,15] repertorial analysis was done [Table 1]. The following characteristic symptoms were considered for repertorisation:

- Sadness and depressed
- Despair and frustrated in life
- Irritable easily and affected by small things
- Indecisive, lack of self confidence
- Forgetful, cannot remind things where kept
- Washing habit, always busy to clean home
- Infertility
- Hydrosalpinx
- Menses irregular, mostly late
- Menses – Scanty, dark, clotted, offensive
- Painful, dysmenorrhoeal < before menses
- Leucorrhoea – thick, mucus, acrid, with itching in vagina and vulva pudenda
- Desire for spicy foods⁺⁺⁺
- Desire for cold food⁺⁺⁺
- Disturbed sleep < first night for thinking
- Profuse offensive perspiration on the palm and sole
- Recurrent ulceration of the mouth and tongue with irregular patches
- Caries in teeth with decayed at edged
- Tumour/fibroadenoma in the left breast
- Constipation – Hard and dry stool.

Clinical findings and diagnostic assessment

On previous clinical findings and investigations, it was found to be a case of gross endometriosis with a history of right ovarian cystectomy on 14 June 2010 with primary subfertility. On 30 March 2011, hysteroscopy revealed a hyperplastic

congested uterus with both ostia seen; laparoscopy revealed extensive endometriosis surrounding the left ovary and healthy looking left fallopian tube [Figure 1]. Furthermore, HSG revealed right-sided fallopian tubal block with patent left-sided fallopian tube with spillage [Figure 2]. In 2015, reproductive hormonal profile revealed decreased AMH and increased FSH that suggested decreased OR. Decreased OR refers reduced production of quality ovum from the maturing follicle during menstrual cycle. On 9 March 2015, TVS USG [Figure 3] also revealed right hydrosalpinx. It was found that it was subfertility with dual pathology of poor Ovarian Reserve along with one-sided tubal blockage (h/o right hydrosalpinx). She had taken treatment for natural conception along with on-off treatment by gynaecologists and obstetricians from 2011 to 2015 by gynaecologists and fertility specialists. Finally, she was advised for a course of normal treatment with dehydroepiandrosteridione for 6 months with a hope to stimulate the ovarian function, but there was no improvement for subsequent level of AMH (<1, indicates POR) and FSH (increased, 16.25) [Figure 4]. There was failure of normal conception; ultimately, the fertility specialist advised her for IVF with donor ovum [Figure 5], for which the patient was unable to afford the expenses.

Based on detailed workup by different gynaecologists and therapist’s clinical evaluation, this was found to be a case of subfertility due to dual pathology of severe endometriosis and POR. There were associated fibroadenoma breast and depression with obsessive behaviour.

Table 1: Repertorisation chart

Symptoms		Count
01. MIND - SADNESS		2 625
02. MIND - IRRITABILITY		3 570
03. MIND - CONFIDENCE - want of self-confidence		2 161
04. MIND - WASHING - desire to wash		3 3
05. GENERALS - FOOD and DRINKS - spices - desire		3 83
06. GENERALS - FOOD and DRINKS - cold food - desire		3 62
07. PERSPIRATION - ODOR - offensive		2 122
08. EXTREMITIES - PERSPIRATION - Foot - Sole - offensive		3 6
09. FEMALE GENITALIA/SEX - STERILITY		3 107
10. FEMALE GENITALIA/SEX - HYDROSALPINX		2 1
11. FEMALE GENITALIA/SEX - MENSES - late, too		3 211
12. FEMALE GENITALIA/SEX - MENSES - scanty		2 224
13. FEMALE GENITALIA/SEX - MENSES - painful		3 292
14. FEMALE GENITALIA/SEX - LEUKORRHOEA - acrid, exorciating		2 143
15. CHEST - TUMORS - Mammae		1 32
16. MOUTH - ULCERS - Tongue		2 91
17. STOOL - HARD		2 337

	sil.	nat.m.	ars.	am-c.	phos.	puis.	merc.	lach.	nux-v.	caust.	sulph.	lyc.	aur.	zinc.	calc.	verat.	apis.	chin.
01.	35	72	32	32	31	30	30	30	30	29	27	27	27	27	27	27	27	27
02.	68	60	60	53	75	77	62	61	55	55	69	54	52	51	51	46	45	44
03.																		
04.																		
05.																		
06.																		
07.																		
08.																		
09.																		
10.																		
11.																		
12.																		
13.																		
14.																		
15.																		
16.																		
17.																		

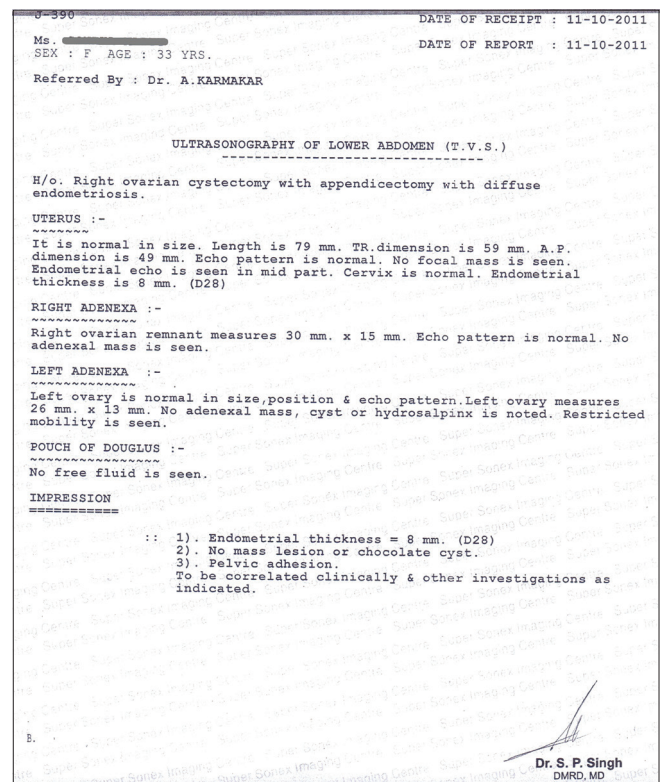


Figure 1: Ultrasonography of the lower abdomen (before treatment)

Parveen and Bhaumik: Successful homoeopathic treatment of infertility with endometriosis and poor ovarian reserve being advised for donor-ovum-IVF


V.Id.:11J05129	Booking Date:21/10/11
Patient Name [Redacted]	Report Date :21/10/11
Age:32y, Sex:F	
Referred by Dr. (Mrs.) Aparna Karmakar	
Digital X-Ray Hysterosalpingography (HSG)	DR - 39
R E P O R T	
Uterine cavity is normal.	
Both tubes opacified.	
On left side peritoneal spillage seen.	
On right side no peritoneal spillage noted.	
 DR. P. K. PAL, DMRD, MD Consultant Radiologist	

Figure 2: HSG report (before treatment)


Pelvic Ultrasound Report	
Date: 09.03.2015	
Name : [Redacted]	
Age : 35 years	
Method: Transvaginal	
Indication: Primary Subfertility	
Uterus and adnexae: Adenomyotic, axial normal sized uterus measuring 65 x 45 x 45 mm. Clear endometrial echo with maximum thickness of 5.0 mm (LMP: 25.02.15). No obvious fibroids or adenomyoma.	
Right ovary is not seen (? Removed). An elongated structure seen in right adnexa ? right hydrosalpinx. Left ovary measures 31 x 20 x 25 mm. (volume 8.08 cc).	
No free fluid in POD.	
Findings: Right hydrosalpinx.	
 Dr. Moumita Naha	

Figure 3: Ultrasonography (transvaginal) of the pelvis (before treatment)

Therapeutic intervention, follow-up and outcome

Homoeopathic medicines were procured from Hahnemann Publishing Company Pvt. Ltd. (Good Manufacturing Practice certified ISO 9001:2008 unit) and dispensed from DACRRI (H) dispensary. The homoeopathic *Similimum* was prescribed on the basis of individualisation, symptom totality and miasmatic analysis with the holistic concept of Homoeopathy. Treatment was started with constitutional homoeopathic medicine *Silicea* with increasing potencies (200C, 1M, 10M). Further, through miasmatic analysis, *Syphilinum* was prescribed as an inter-current remedy.

Detailed follow-up is summarised in Table 2.

Although *Silicea* initiated the improvement, *Syphilinum* completed the cure, i.e., the patient became pregnant [Figure 6 - USG report of pregnancy] and gave birth to a healthy male baby [Figure 7, Birth registration Certificate].

The final outcome and possible causal attribution of the changes in this case were assessed using the 'Modified Naranjo Criteria' as proposed by the HPUS Clinical data Working Group (December 2015) [Table 3].

The total score of outcome as per the Modified Naranjo Criteria was 09, which was close to the maximum score of 13. This explicitly shows the positive causal attribution of the individualised homoeopathic treatment towards this case of infertility.^[16]

DISCUSSION

This case report followed HOM-CASE guidelines for reporting the outcomes. This case was a confirmed case of subinfertility in an elderly primigravida with dual pathology, POR with one-sided tubal block along with decreased AMH and increased FSH. There was no chance of normal conception

without IVF with donor ovum as per the fertility specialist or the gynaecologist and the obstetrician after their treatment from 2011 to 2015.

As per homoeopathic philosophy, pathology does not fully represent the expression of disease in a given case. The true pathognomic symptoms of a given case are those that cover the existing active miasm. Hahnemann says that the primitive disease evidently owed its existence to some chronic miasm. To reach the prima causa miasmatic prescription was based on the basic miasmatic symptoms of the case. In-depth understanding of dominant miasm of the patient through the totality of symptoms, individualisation, personal history and family and past histories can give insight to the morbid susceptibility and bring out cure.^[17-21]

In this case, the miasmatic analysis was based on the dominant symptoms of the *Syphilis* miasm such as pathological symptoms (infertility, POR [premature degeneration, hydrosalpinx, history of endometriosis, delayed menses and acrid, excoriating leucorrhoea]; mental symptoms [sad, depressed, despair, irritability, aversion to speak, obsession such as washing habit]; physical symptoms [emaciated with swollen glabella with protruded forehead, desire for cold food and spicy foods, recurrent mouth ulcer with salivation and profuse offensive perspiration]; other symptoms [caries teeth, decayed at the edges, black and brittle nails, constipated with hard, dry stool] and family history of insanity, cancer and osteoporosis.^[22-23] In the female genitalia chapter of The Essential Synthesis Repertory under the rubric 'Sterility', *Syphilinum* is presented as the 2nd grade medicine. Therefore, *Syphilinum* (200, 1M) was prescribed as an anti-miasmatic drug to complete the treatment process in this patient, resulting a positive outcome i.e. the patient became pregnant and delivered a healthy male baby.

Table 2: Timeline including follow-up of the case

Date of visit	Symptoms/indications	Prescribed medicine with potency & doses
01 July 2015	Baseline presentation; LMP - 15 June 2015	<i>Silicea</i> 200/4Doses(D)/Twice daily (BD)
20 July 2015	No menses occur till date; No changes occur. All symptoms are stand still	<i>Silicea</i> 1M/2D/Once daily (OD)
14 August 2015	Sadness, despair, irritability - as earlier; washing mania - no change, Disturbed sleep; LMP - 22 July 2015; Menses occurred at 37 days, Dysmenorrhoea, severity of pain - less and more menstruation blood flow, lasting 4-5 days; no change in leucorrhoea; Ulceration of mouth and tongue persists, with passage of hard, dry stool at 1-2 days' interval; not reduced in the size of FA (clinically)	<i>Silicea</i> 1M/1 dose/OD
07 September 2015	Sadness, depression, despair - same but irritability increased; obsession, washing mania - also increased; Sleep - disturbed No conception; LMP - 21 August 2015; Menses occurs at 30 days, flow normal, dysmenorrhoea - less, pain occurs only for few hours during menses; other symptoms are not improved, stand still condition	<i>Silicea</i> 10M/1 dose
30. September 2015	LMP - 18 September 2015, at 28 days, i.e., Menstruation cycle - regular Deteriorated mental condition, more depressed, frustrated, with increased irritability and obsession, like washing mania also increased; disturbed sleep Leucorrhoea - increased in quantity and acidity, with vaginal itching; increased mouth and tongue ulcer, with passage of hard, dry stool at 1-day interval On further analysing the case on the basis of predominant syphilitic miasm, <i>Syphilinum</i> was prescribed by which miasmatic obstacles are depleted	<i>Syphilinum</i> 200/2 doses/OD × 2 days
14 October 2015	No improvement in mental condition Other symptoms such as leucorrhoea and ulceration of mouth and tongue - mild better; but passes hard stool daily. FA size - same	Placebo 200/BD × 15 days
04 November 2015	Mentally - feels little better, sad, depressed but less irritability washing mania - reduced; Sleep - good than earlier LMP - 17 October 2015, Menses occurs at 29 days, Menstruation cycle - regular, painless, with normal flow, leucorrhoea - less, no vaginal itching; Mouth and tongue ulcer - disappeared; stool - hard, passes daily; no change in FA	Placebo 200/BD × 15 days
27 November 2015	LMP - 15 November 2015, Menses occur at 28 days, regular, painless, menstrual cycle, normal flow, but fail to normal conception; leucorrhoea - less with no acidity. She became more anxious for conception, more sad, depressed, Washing mania - not reduced further; sleep - disturbed again Mouth and tongue ulcer - recurred but with less severity; Stool - hard, but passes daily, but no change in FA	<i>Syphilinum</i> 1M/2Doses/OD
19 December 2015	LMP - 14 December 2015; Stand still condition in all symptoms and medicine were repeatedly prescribed for further improvement	<i>Syphilinum</i> 1M/1D
23 January 2016	No menses, 9 days crossed from LMP (14 December 2015). Then urine test was advised for pregnancy	No medicine
29 January 2016	Urine pregnancy test came out to be positive (test done on 27 January 2016 in DACRRI [H]). She became so happy, advised for USG of pelvis	No medicine
15 February 2016	USG of pelvis was done on 10 February 2016 - Single live foetus [Figure 6]; after that, she was referred to the hospital for proper antenatal check-up and future planning for delivery under the guidance of gynaecologist and obstetrician During pregnancy, she was also treated with homoeopathic medicines for nausea vomiting, morning sickness and backache On 11 November 2016, she delivered a healthy male baby at a local nursing home by caesarean section [Figure 7]	-

LMP: Last menstrual period

Kalampokas *et al.*^[24] presented a case series of treated female infertility in the literature in which homoeopathic treatment showed positive/successful result on five female subfertility patients in a large obstetrics-gynaecology hospital in Athens, Greece. However, there is lack of any well-designed study to support the results of these case reports.

In the review article of 'Homeopathic treatment of infertility: A medical and bioethical perspective', the author has observed the homoeopathic approach and the bioethical implications to infertility and proposed that monitoring the effects of homoeopathic remedies on infertile women may be an effective

method to assess the efficacy of this form of alternative medicine. Infertility is a popular area for homoeopathic applications as the complementary and alternative medicine.^[25]

CONCLUSION

- Constitutional homoeopathic treatment has helped an elderly primi to conceive normally despite her established subfertility due to the dual pathology of endometriosis and decreased OR
- It reconfirms the homoeopathic constitutional treatment on miasmatic analysis and holistic basis over clinical diagnosis

Table 3: Assessment by Modified Naranjo Criteria score

Item	Yes	No	Not sure or N/A
Was there an improvement in the main symptom or condition for which the Homoeopathic medicine was prescribed?	+2		
Did the clinical improvement occur within a plausible time frame relative to the drug intake?	+1		
Was there an initial aggravation of symptom? (need to define in glossary)			0
Did the effect encompass more than the main symptom or condition, i.e., were other symptoms ultimately improved or changed?	+1		
Did overall well-being improve? (suggest using a validated scale)	+1		
Direction of cure: Did some symptoms improve in the opposite order of the development of symptoms of the disease?			0
Direction of cure: Did at least two of the following aspects apply to the order of improvement of symptoms: from organs of more importance to those of less importance, from deeper to more superficial aspects of the individual, from the top downwards			0
Did 'old symptoms' (defined as non-seasonal and non-cyclical that were previously thought to have resolved) reappear temporarily during the course of improvement?		0	
Are there alternate causes (other than the medicine) that, with a high probability, could have caused the improvement? (consider known course of disease, other forms of treatment and other clinically relevant intervention)		+1	
Was the health improvement confirmed by any objective evidence? (e.g., lab test, clinical observation, etc.)	+2		
Did repeat dosing, if conducted, create similar clinical improvement?	+1		
Total score=9			

N/A: Not available

Name	██████████	Collected	31/8/2015 10:23:00AM
Lab No.	121947237	Age	35 Years
Gender	Female	Reported	1/9/2015 3:38:32PM
A/c Status	P	Ref By	DR MANAS KUNDU
Report Status	Final		

Test Name	Results	Units	Bio. Ref. Interval
ANTI MULLERIAN HORMONE; AMH,SERUM @ (EIA)	0.97	ng/mL	

AMH LEVEL IN ng/mL	Remarks
<0.50	Predictive of poor response
0.50 - <1.0	Suggestive of limited ovarian reserve
1.00 - 3.50	Predictive of optimal response
>3.50	Predictive of Ovarian hyperstimulation syndrome/PCOS

FSH; FOLLICLE STIMULATING HORMONE, SERUM (Chemiluminescent Immunoassay)	16.25	mIU/mL
---	-------	--------

Figure 4: Hormone profile (before treatment)

- Well-designed studies are required for establishing the effectiveness and efficacy of Homoeopathy in treating infertility cases. It may provide the scientific validity on the medical benefits of Homoeopathy.

Acknowledgements

The author is grateful to Dr D. B. Sarkar, Assistant Director, DACRRI (H), Kolkata, for editing this case report. The author acknowledges the fertility specialist Dr Kousiki Roy, Department of Gynaecology, AMRI, Kolkata, for helping in the case study of literature review for this case report and valuable suggestions.

The author would also like to acknowledge the patient for her consent and co-operation in continuing the follow-up.

Informed consent

The patient willingly gave her informed consent for publication of this report.

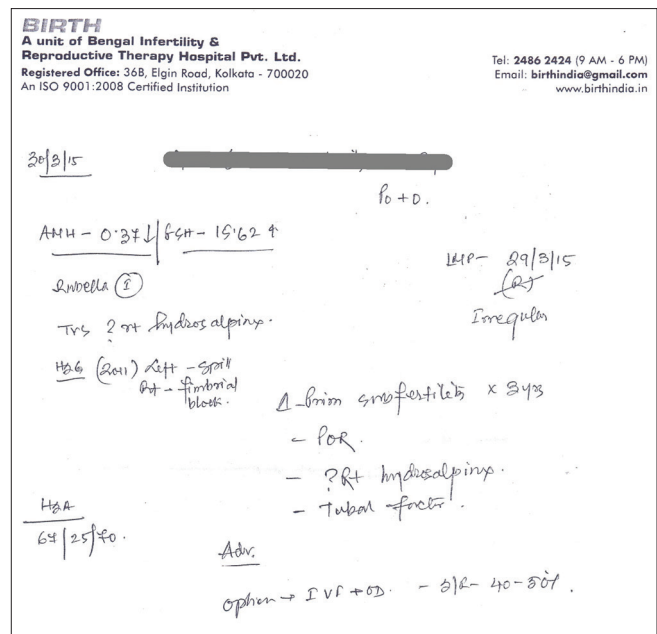


Figure 5: Advice from fertility specialist for *in vitro* fertilisation with donor ovum

Declaration of patient consent

The authors certify that they have obtained all appropriate patient consent forms. In the form, the patient has given her consent for her images and other clinical information to be reported in the journal. The patient understands that her name and initials will not be published and due efforts will be made to conceal identity, but anonymity cannot be guaranteed.

Financial support and sponsorship

Nil.

Parveen and Bhaumik: Successful homoeopathic treatment of infertility with endometriosis and poor ovarian reserve being advised for donor-ovum-IVF

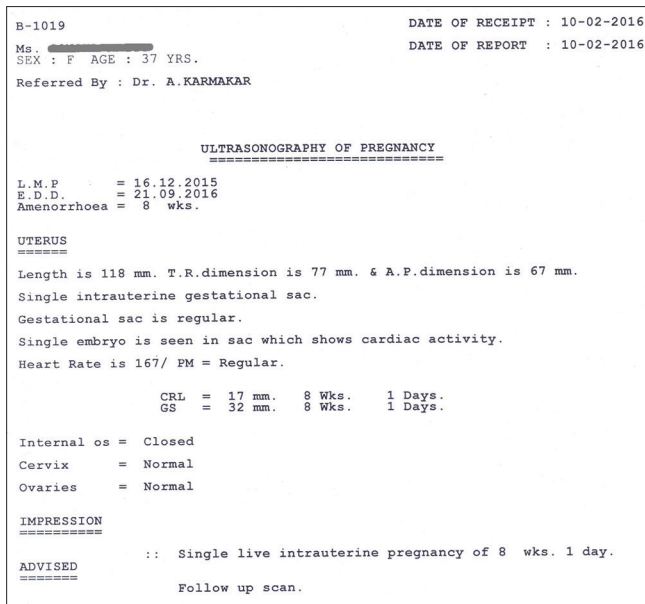


Figure 6: Ultrasonography of pregnancy (after treatment)

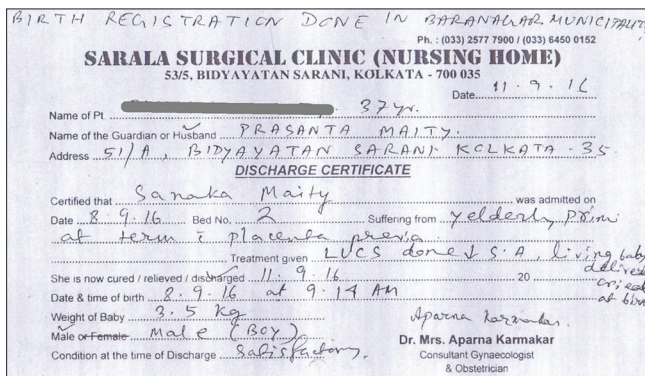


Figure 7: Birth registration certificate of the male child

Conflicts of interest

None declared.

REFERENCES

- World Health Organization (WHO)-International Committee for Monitoring Assisted Reproductive Technology (ICMART), [Sexual and reproductive health], WHO; <https://www.who.int/reproductivehealth/topics/infertility/definitions/en/>. [Last accessed on 2017 Sep 16].
- Infertility, Wikipedia; Available from: <https://www.en.wikipedia.org/wiki/Infertility>. [Last accessed on 2017 Sep 15].
- Mascarenhas MN, Flaxman SR, Boerma T, Vanderpoel S, Stevens GA. National, regional, and global trends in infertility prevalence since 1990: A systematic analysis of 277 health surveys. *PLoS Med* 2012;9:e1001356.

- Olooto WE, Adeleye AO, Amballi AA, Banjo TA. A review of female infertility; important etiological factors and management. *J Microbiol Biotechnol Res* 2012;2:379-85.
- Acien P, Velasco I. Endometriosis: A disease that remains enigmatic. *ISRN Obstet Gynecol* 2013;242149.
- Koninckx PR, Martin DC. Deep endometriosis: A consequence of infiltration or retraction or possibly adenomyosis externa? *Fertil Steril* 1992;58:924-8.
- Macer ML, Taylor HS. Endometriosis and infertility: A review of the pathogenesis and treatment of endometriosis-associated infertility. *Obstet Gynecol Clin North Am* 2012;39:535-49.
- Koninckx PR, Martin D. Treatment of deeply infiltrating endometriosis. *Curr Opin Obstet Gynecol* 1994;6:231-41.
- Subrat P, Santa SA, Vandana J. The concepts and consequences of early ovarian ageing: A caveat to women's health. *J Reprod Infertil* 2013;14:3-7.
- te Velde ER, Pearson PL. The variability of female reproductive ageing. *Hum Reprod Update* 2002;8:141-54.
- Abdalla H, Thum MY. An elevated basal FSH reflects a quantitative rather than qualitative decline of the ovarian reserve. *Hum Reprod* 2004;19:893-8.
- Broekmans FJ, Kwee J, Hendriks DJ, Mol BW, Lambalk CB. A systematic review of tests predicting ovarian reserve and IVF outcome. *Hum Reprod Update* 2006;12:685-718.
- The National Infertility Association. (Family Building Options/Donor Options/Using Donor egg), NIA. Available from: <http://www.resolve.org>. [Last accessed on 2017 Sep 16].
- Schroyens F. RADAR 10, Synthesis Repertorium Homeopathicum Syntheticum, 9.1 version, Archibel Homoeopathic Software, Belgium 2009.
- Schroyens F. The Essential Synthesis Repertory. 9.1 version. Rep. Indian Edition. New Delhi: B. Jain Publishers (P) Ltd.; 2012. p. 1050, 1089.
- van Haselen RA. Homeopathic clinical case reports: Development of a supplement (HOM-CASE) to the CARE clinical case reporting guideline. *Complement Ther Med* 2016;25:78-85.
- Boericke W. Pocket Manual of Homoeopathic *Materia Medica* and Repertory. 50th Impression. New Delhi: B. Jain Publishers (P) Ltd.; 2010. p. 590-4, 627-8.
- Allen HC. Keynotes and Characteristics with Comparisons of Some of the Leading Remedies of the *Materia medica* with Bowel Nosodes. Rep ed. New Delhi: B. Jain Publishers (P) Ltd.; 2004. p. 264-7, 282-4.
- Hahnemann S. Organon of Medicine. 6th ed. New Delhi: B. Jain Publishers (P) Ltd.; 2011.
- Kent JT. Lectures on Homoeopathic Philosophy. New Delhi: B. Jain Publishers (P) Ltd.; 2011. p. 231-41.
- Hahnemann S. The Chronic Diseases, their Peculiar Nature and their Homoeopathic Cure. Rep ed. New Delhi: B. Jain Publishers (P) Ltd.; 1978. p. 1397-436.
- Allen JH. The Chronic Miasms Psora and Pseudo-Psora. Rep ed., Vol. I & II. New Delhi: B. Jain Publishers (P) Ltd.; 2006. p. 51-277.
- Speight P. A Comparison of the Chronic Miasms, Psora, Pseudopsora, Syphilis, Sycosis. Rep ed. New Delhi: B. Jain Publishers (P) Ltd.; 1998. p. 1-87.
- Kalampokas T, Botis S, Kedikgianni-Antoniou A, Papamethodiou D, Kivellos S, Papadimitriou V, et al. Homeopathy for infertility treatment: A case series. *Clin Exp Obstet Gynecol* 2014;41:158-9.
- Masiello DJ, Loike JD. Homeopathic Treatment of Infertility: A Medical and Bioethical Perspective. *Int J Complement Alt Med* 2017;5:00167.

‘बांझपन के उपचार में व्यक्तिगत होम्योपैथी का प्रभाव—एक केस रिपोर्ट’

सार

कुछ वर्षों तक स्त्रीरोग विशेषज्ञ द्वारा बांझपन के उपचार के बाद, एक 37 वर्षीय महिला जो 6 वर्ष से विवाहिता थी को होम्योपैथिक बाहरी रोगी विभाग (ओपीडी) में प्रस्तुत किया गया। शादी के एक साल बाद अन्तर्गर्भाशय-अस्थानता के लिए अपातकालीन डिम्बग्रंथी पुटी-उच्छेदन की पूर्व इतिवृत्त थी। अनुवर्ती बांझपन से यह प्रकट हुआ की कम डिम्बग्रंथि संशय के साक्ष्य रोगी एक तरफा डिम्बप्रणालीय बाधा के साथ एक विशेष प्रकार के डिंबवाही नलिका के अवरोध से ग्रस्त थी। उनके पति का वीर्य विश्लेषण सामान्य था और उन्हें डोनर-ओवम इन-विट्रो-फर्टीलाइजेशन (आईवीएफ) के लिए सलाह दी गई थी। इस स्थिति के लिए उन्हें छः माह के लिए होम्योपैथी की समग्र अवधारणा के साथ संवेदी विश्लेषण के बाद संवैधानिक होम्योपैथिक औषधि द्वारा उपचारित किया गया। उपचार साइलिशिया से शुरू हुआ और बाद में सिफिलिनम दी गई। रोगी ने उसके बाद सामान्य रूप से गर्भ धारण किया और बाद में पूर्ण अवधि में स्वस्थ बच्चे को जन्म दिया। यह मामला उप प्रजनन पर मान्य होम्योपैथिक उपचार की सकारात्मक भूमिका को दर्शाता है।

‘Effet de l'homéopathie individualisée dans le traitement de l'infertilité - Un rapport de cas’

RÉSUMÉ:

Une femme de 37 ans, mariée depuis six ans, s'est présentée au service des consultations homéopathiques externes après avoir suivi pendant quelques années un traitement contre l'infertilité prescrit par un gynécologue. Elle avait des antécédents de cystectomie ovarienne d'urgence pour endométriose qui ont eu lieu un an après son mariage. Son bilan d'infertilité a révélé un hydrosalpinx avec obstruction des trompes de Fallope d'un coté ainsi que des signes de réserve ovarienne faible. L'analyse du sperme de son mari était normale et une fécondation in vitro par le biais de donneur d'ovules (fécondation in vitro) lui avait été conseillée. À ce stade, elle a été traitée sur une période de six mois selon la médecine homéopathique constitutionnelle à la suite d'une analyse miasmatisque en suivant un concept holistique d'homéopathie. Le traitement a commencé avec Silicea puis est passé à Syphilinum. Elle est tombée enceinte normalement après cela et a accouché par la suite d'un bébé en bonne santé et à terme. Ce cas montre le rôle positif du traitement homéopathique classique pour la sous-fertilité.

“Efecto de la homeopatía individualizada en el tratamiento de la infertilidad: reporte de un caso”

RESUMEN

Una mujer de 37 años, casada desde hace 6 años se presentó en el ambulatorio homeopático después de haberse sometido a un tratamiento de infertilidad por su ginecólogo. En sus antecedentes cabe destacar una cistectomía ovárica de urgencias por endometriosis, un año después de haberse casado. El posterior estudio de infertilidad reveló una hidrosalpingitis con un bloqueo tubárico unilateral junto con la evidencia de una falta de reserva ovárica. El análisis del semen del marido dio resultados normales. A la paciente se le recomendó recurrir a una fertilización *in vitro* con óvulo donante. En este punto, la trataron con medicina homeopática constitucional después del análisis miasmático con el concepto holístico de homeopatía durante seis meses. Al principio se le prescribió *Silicea* y después *Syphilinum*. Este tratamiento le permitió concebir de forma natural y después dar a luz a un niño a término. Este caso demuestra el papel positivo del tratamiento homeopático en la infertilidad.

“Effekt der individualisierten Homöopathie bei der Behandlung von Unfruchtbarkeit - Ein Fallbericht”

ABSTRAKT:

Eine 37-jährige Frau, seit sechs Jahren verheiratet, wurde der homöopathischen “Out-Patient”-Abteilung (OPD) übergeben, nachdem sie von einem Gynäkologen über einige Jahre hinweg wegen Unfruchtbarkeit behandelt worden war. Sie hatte ein Jahr nach ihrer Heirat eine Notfall-Ovarialzystektomie wegen Endometriose. Ihre anschließende Unfruchtbarkeitsuntersuchung ergab Hydrosalpinx mit einseitiger Tubenblockade zusammen mit Anzeichen einer schlechten Ovarialreserve. Die Samenanalyse ihres Mannes war normal und wurde für die In-vitro-Fertilisation (IVF) von Spender-Eizellen empfohlen. Zu diesem Zeitpunkt wurde sie nach der miasmatischen Analyse mit dem holistischen Konzept der Homöopathie über einen Zeitraum von sechs Monaten mit konstitutionellen homöopathischen Arzneien behandelt. Die Behandlung begann mit *Silicea* und wurde später auf *Syphilinum* umgestellt. Danach wurde sie normal schwanger und gebareingesundes Kind zur regelgerechten Niederkunftszeit. Dieser Fall zeigt die positive Rolle der klassischen homöopathischen Behandlung bei Fertilität.

個案報告：個人化順勢療法對不孕症的治療

摘要：

一名37歲、結婚6年的婦人，經過婦科醫生治療不孕症數年之後，來到順勢療法門診病人部門（OPD）。她婚後一年曾因子宮內膜異位而緊急進行卵巢囊腫切除術。隨後進行的不孕症檢查顯示輸卵管積水，有單側輸卵管阻塞，證實卵巢儲備不足。她丈夫的精液分析正常，建議進行捐贈卵子體外受精（IVF）。這時候，她接受了個人化順勢療法療劑（運用瘴氣分析）治療，並跟從順勢療法的整全概念超過6個月。治療初期使用矽（Silicea），隨後更換為梅毒（Syphilinum）。她在治療之後正常受孕，後來足月分娩出健康的嬰兒。此個案顯示出古典順勢療法對低生育力有積極作用。